

**PATIENT**

Hunter Amsden

**PRESENTING CLINICAL SIGNS**

History: Grade IV/VI systolic heart murmur. Assess prior to dental. BP: 127/88, 130/92, 130/92mmHg.

**SPECIES**

Canine

**ELECTROCARDIOGRAPHIC FINDINGS** \*Note: Single lead ECGs are evaluated as a rhythm strip. Morphology/MEA cannot be definitively commented on.

A single lead ECG is available; 25mm/s, 10mm/mV. The average heart rate is 90bpm (range 75-100bpm). The rhythm is sinus in origin, with a p for every QRS complex and vice versa. The P and QRS morphologies are positive. No ectopic beats, pauses or other dysrhythmias observed. ECG diagnosis: Normal sinus rhythm with respiratory variation.

**BREED**

Coton de Tulear

**SEX**

Male Neutered

**ECHOCARDIOGRAM FINDINGS**

2D, m-mode, color flow and doppler imaging is available. Diffuse thickening of mitral valve leaflets (anterior>posterior) with mild prolapse into the left atrial lumen. Moderate eccentric mitral regurgitation with moderate left atrial dilation. Normal MR velocity. Mildly increased LV diameter with adequate myocardial function. The tricuspid valve appears subjectively normal, with no significant tricuspid regurgitation. Normal right atrial and ventricular diameter. The pulmonic and aortic valves are normal in morphology and mobility. Normal pulmonic and aortic outflow velocities. No aortic and trace pulmonic insufficiency. No pericardial or pleural effusion noted. No cardiac tumors observed.

**AGE**

11 years

**WEIGHT**

11.8lbs

**CARDIAC CHART**

**INTERPRETED BY**

Maggie Machen Lamy, DVM, DACVIM (Cardiology)

CANINE CARDIAC PARAMETERS	MR VMAX (m/s)	TR VMAX (m/s)	LA/AO (Boon method)	LA/AO (Heart Base; Swe)	FS (%)	EF (%)	EPSS (cm)
<b>NORMAL PARAMETER</b>	4.5-5.5	<2.7	1.3	<1.6	28-40	40-100	<0.6
<b>PATIENT</b>	5.0	NA	1.6	2.2	50	84	0.2
CANINE CARDIAC PARAMETERS	HR (BPM)	AV VMAX (m/s)	PV MAX (m/s)	BODY WEIGHT (kg)	LA 2D short axis Base view (cm)	LVIDd Avg; 2D and m-mode short axis (cm)	LVIDs Avg; 2D and m-mode short axis (cm)
<b>NORMAL PARAMETER</b>	50-100	0.7-1.7	0.7-1.6	BELOW	BELOW	BELOW	BELOW
<b>PATIENT</b>	NM	1.0	0.6	5.4	2.8	3.6	1.9
*Normal chamber parameters expressed as a mean value (SD)				3	1.27 (5.3)	2.46 (2.46)	1.36 (5.5)
<b>BODY WEIGHT DEPENDENT PARAMETERS</b>				5	1.40 (4.5)	2.74 (5.2)	1.60 (4.7)
*Note: All measurements based upon multi-modal images and methods. An average value is reported.				10	1.50 (3.8)	3.27 (3.5)	2.06 (3.1)
				15	1.83 (2.0)	3.71 (2.4)	2.43 (2.1)
				20	2.02 (1.9)	4.14 (2.2)	2.80 (2.0)
				25	2.18 (2.4)	4.48 (2.9)	3.10 (2.5)
				30	2.33 (3.3)	4.83 (3.9)	3.39 (3.4)
				35	2.48 (4.3)	5.17 (5.0)	3.69 (4.5)
				40	2.62 (5.2)	5.48 (6.1)	3.96 (5.4)
				50	2.88 (7.1)	6.07 (8.3)	4.46 (7.4)

Adapted from June Boon, Veterinary Echocardiography, 1998  
 Rishniw M and Hollis NE, J Vet Intern Med 2000; 14:429-435  
 Hansson et al, Vet Rad and Ultrasound 2002  
 Bonagura et al. Echocardiography: principles of interpretation, Vet Clin North Am 15:1177, 1995

**IMAGING PERFORMED BY**

Jennifer Todd, DVM

**HOSPITAL NAME**

Lambs Gap Animal Hospital

**REFERRING VET**

Dr. Todd

**INVOICE**

26074

**DATE**

8/29/22



**PATIENT**

Hunter Amsden

**SPECIES**

Canine

**BREED**

Coton de Tulear

**SEX**

Male Neutered

**AGE**

11 years

**WEIGHT**

11.8lbs

**INTERPRETED BY**

Maggie Machen Lamy,  
DVM, DACVIM  
(Cardiology)

**IMAGING PERFORMED BY**

Jennifer Todd, DVM

**HOSPITAL NAME**

Lambs Gap Animal  
Hospital

**REFERRING VET**

Dr. Todd

**INVOICE**

26074

**DATE**

8/29/22

**INTERPRETATION OF THE FINDINGS & FURTHER RECOMMENDATIONS**

Chronic degenerative valve disease causing moderate mitral regurgitation. Moderate left atrial enlargement indicates there is relatively low risk for imminent complication, however risk for progression to spontaneous congestive heart failure in the future is elevated. No additional issues are identified. The ECG is unremarkable with a normal sinus rhythm.

Given the risk for progression and results of the EPIC trial, Pimobendan is indicated in this patient as below. Assessment of progression in the future will help predict long term outcome, however prognosis is guarded at this stage (B2).

Omega fatty acid supplementation and mild salt restriction may also be of some long-term benefit. Monitor for development of a progressive cough, labored breathing, exercise intolerance or collapse episodes.

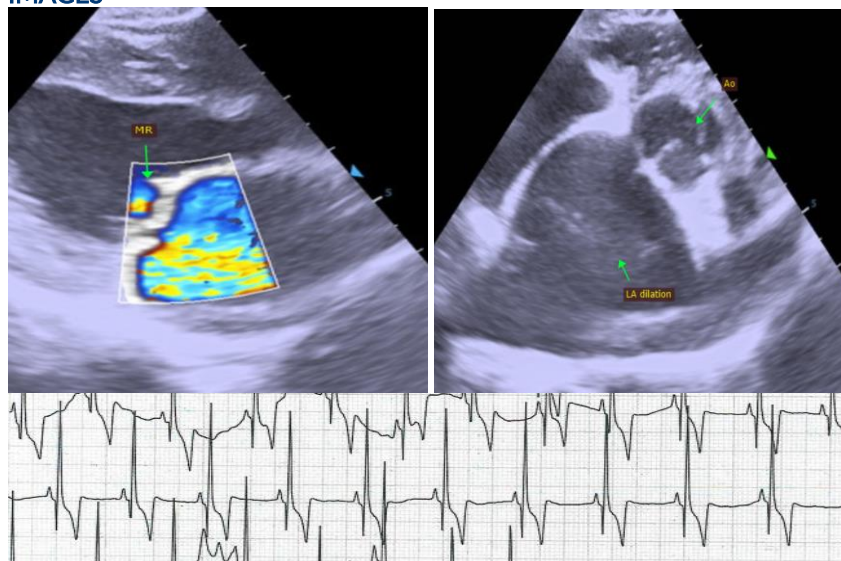
Once on the medication for 3-5 days, anesthetic risk is considered mildly elevated. Cardiac protective drug choices (opioid/benzodiazepine premedication, Propofol or alfaxalone induction, iso or sevo gas) are recommended. Monitor for arrhythmias, hypotension, and hypoxia both intra and post-operatively and intervene as necessary. Judicious IV fluid rates are recommended to avoid fluid overload. Avoid heart rate stimulating drugs such as atropine unless clinically indicated.

**PLAN**

Institute heart muscle support Pimobendan 0.25-0.3mg/kg PO q12h.

Recommend monitor for progression with a recheck echocardiogram in 6 months, sooner if any development of clinical signs.

**IMAGES**





**PATIENT**

Hunter Amsden

The information and recommendations provided are based on the images presented by the referring veterinarian. No evaluation can be communicated regarding pathology that was not visible in the image/video clips provided.

**SPECIES**

Canine

Thank you for this referral. This report was generated using transcription software, and minor dictation errors may be present. If the clinical or image interpretation does not parallel your findings or if I can be of any further assistance, please contact me.

**BREED**

Coton de Tulear

Maggie Machen Lamy, DVM  
Diplomate of the American College of Veterinary Internal Medicine (Cardiology)  
info@sonopath.com

**SEX**

Male Neutered

**AGE**

11 years

**WEIGHT**

11.8lbs

**INTERPRETED BY**

Maggie Machen Lamy,  
DVM, DACVIM  
(Cardiology)

**IMAGING  
PERFORMED BY**

Jennifer Todd, DVM

**HOSPITAL NAME**

Lambs Gap Animal  
Hospital

**REFERRING VET**

Dr. Todd

**INVOICE**

26074

**DATE**

8/29/22